

Acute pyelonephritis and myositis after carboxytherapy : A case report

KyungHoon Sun¹, JunHo Heo², Yong Hwang^{2*}

¹Department of emergency medicine, Chosun university, college of medicine

²Department of Emergency Medicine, Wonkwang University, School of Medicine

카르복시테라피 후 발생한 급성 신우신염 및 근육염 : 증례 보고

선경훈¹, 허준호², 황 용^{2*}

¹조선대학교의과대학 응급의학과교실, ²원광대학교의과대학 응급의학과교실

Abstract Carboxytherapy is very similar to mesotherapy in terms of methods, conditions it treats, and outcomes. An important difference consider, however, is that carboxytherapy administers carbon dioxide gas into the subcutaneous layer, just underneath the skin, whereas mesotherapy administers a cocktail of vitamins, minerals, and drugs and into the mesoderm of the skin. There have been many previous case reports of complications of mesotherapy such as hematoma, granulomatous panniculitis, cellulitis, and abscesses. However, complications of carboxytherapy have rarely been reported because the carbon dioxide gas is absorbed within a week and is infused into the subcutaneous and superficial layers. A 27-year-old woman who had twice undergone carboxytherapy to reduce abdominal fat (3 days and 2 weeks ago) at an oriental medical clinic visited the emergency department due to high fever, myalgia, severe back pain, and subcutaneous emphysema from the buttocks to the lower chest wall area. A computed tomography (CT) scan was performed for diagnosis and treatment. We immediately started broad spectrum antibiotics and consulted with the department of radiology, which could not rule out acute peritonitis due to needle injury. A radiologist confirmed abdominal myositis and needle puncture induced acute pyelonephritis. Pyelonephritis can even lead to septicemia, which can have fatal consequences. Therefore, if the patient has costovertebral or back pain after undergoing needle puncture or acupuncture therapy, the emergency physicians need careful initial evaluation for diagnosis and treatment.

요 약 카르복시테라피(Carboxytherapy)는 메조테라피(mesotherapy)와 방법, 치료 조건 및 결과 면에서 매우 유사하다. 그러나 중요한 차이점은 카르복시테라피는 이산화탄소 가스를 피부 바로 아래의 피하층으로 주입하는 반면 메조테라피는 비타민, 미네랄, 그리고 약물의 혼합물을 주입한다는 것이다. 메조테라피의 합병증으로 혈종, 파누스육아종, 봉와직염, 농양 등 이전에 많은 사례들이 보고되었으나, 카르복시테라피는 피하 및 얇은층에 이산화탄소를 주입하고, 이산화탄소는 주입 1주일 안에 흡수되기 때문에 부작용이 거의 보고 되지 않았다. 3일전과 2주전에 한의원에서 카르복시테라피를 받은 29세 여자 환자가 고열, 근육통, 심한 요통 및 엉덩이 부위부터 아래쪽 흉벽까지 피하 기종을 주소로 응급실에 내원하였다. 진단 및 치료를 위해 컴퓨터 단층 촬영을 시행하였으며, 즉시 영상의학과에 판단을 의뢰하였다. 바늘에 의한 손상으로 인한 급성 복막염을 배제할 수 없어 즉각적인 광범위항생제를 투여하였으며, 판독 결과 근육염과 바늘 손상으로 인한 신우신염이 확진되었다. 신우 신염의 경우 적절한 치료가 이루어지지 않으면 패혈증까지 진행할 수 있어 치명적인 결과를 초래 할 수 있다. 따라서 만일 바늘에 찔리거나 침을 맞은 후에 환자가 늑골척추부위나 허리에 통증이 있는 경우 응급의학과 의사는 진단 및 치료를 위해 신속한 초기 평가가 필요하다.

Keywords : Carboxytherapy, Myositis, Organ injury, Pyelonephritis, Subcutaneous injection

본 논문은 2018학년도 원광대학교의 교비지원에 의해 수행되었음.

*Corresponding Author : Yong Hwang(Wonkwang Univ.)

Tel: +82-10-9656-1582 email: b612sky2@naver.co.kr

Received May 29, 2018

Revised (1st June 15, 2018, 2nd June 21, 2018)

Accepted August 3, 2018

Published August 31, 2018

1. Introduction

Carboxytherapy is minimally-invasive medical procedure using a micro-needle to inject under the skin into the subcutaneous tissue for improvement of scarring, cellulite, and wrinkle reduction[1-4]. Carboxytherapy is very similar to mesotherapy in terms of the methods of the procedure and the conditions it treats. A 27-year-old woman visited to emergency department(ED) in our hospital with fever, headache, vomiting and back pain. Previously, she had undergone carboxytherapy as a cosmetic procedure to reduce abdominal fat at an oriental medical clinic. There are many reports of mesotherapy complications, but rarely of complications due to carboxytherapy[4-7]. This report discusses the rare occurrence of myositis and acute pyelonephritis after carboxytherapy.

2. Case report

A 27-year-old woman was brought by her husband to the emergency department (ED) in our hospital with fever, headache, vomiting and back pain. She had twice undergone carboxytherapy as a cosmetic procedure to reduce abdominal fat (3 days and 2 weeks ago) at an oriental medical clinic. She noted mild chest discomfort and flank pain in both sides following the first treatment and took an analgesic from a local pharmacy for a week for the pain relief. Despite the fact that symptoms were not improved, she underwent a second carboxytherapy procedure. She experienced fever, general ache, and severe flank pain the day after therapy and came to the emergency department as a result. At the system review, she complained of fever, chills, dysuria, and general aching. On physical examination, her vital signs were stable; blood pressure of 140/80 mmHg, heart rate of 98 beats/min, respiration rate of 20 breaths/min, and body temperature was 38.5 °C, but presented with severe back pain and costovertebral angle tenderness on the right side, and subcutaneous emphysema from the buttocks to the lower chest wall on the back and sides

Table 1. Vital sign of Patient

Vital Sign	
Mental state	Alert
Blood pressure	140/80 mmHg
Herat Rate	98 beats/min
Respiratory Rate	20 breaths/min
fever	38.5 °C

(Table 1). She stated that costovertebral pain was exacerbated when the needle was inserted into her back. We performed blood and urine tests and the Focused Assessment with Sonography in Trauma (FAST) to determine the cause of pain and subcutaneous emphysema. The laboratory test results showed a hemoglobin value of 10.9 g/dL, white blood cell count and absolute neutrophil count were elevated to 12,340/mm³ and 11,131/mm³(90.2%), respectively, and serum C reactive protein(CRP) and procalcitonin (PCT), both markers of infection, were elevated to 9.11 mg/dl and 4.27 ng/ml, respectively. Her urinalysis was that WBC many/HPF and RBC 50/HPF (HPF : high power field [x 400]) (Table 2). We decided to perform

Table 2. Laboratory Test Results

Blood test	Hemoglobin	10.9 g/dL
	WBC*	12,340/mm ³
	Neutrophil count(%)	11,131/mm ³ (90.2%)
	CRP**	9.11 mg/dl
Urinalysis	Procalcitonin	4.27 ng/ml
	WBC	many/HPF***
	RBC****	50/HPF

* WBC : White blood cell count
 ** CRP : Serum C reactive protein
 *** HPF : High power field [x 400]
 **** RBC : Red blood cell count

a computed tomography (CT) scan because the FAST was difficult to interpret due to abdominal wall air. An enhanced abdominal CT revealed a lot of gas-forming in the mesoderm and abdominal muscle layer and also a small area of extremely low attenuation on the right kidney (Fig.1A and 1B). Blood culture and urine culture were performed and we started antibiotics (ceftriaxone) due to the possibility of surgery. The tests result was that blood culture was negative and staphylococcus epidermidis was grown in urine culture.

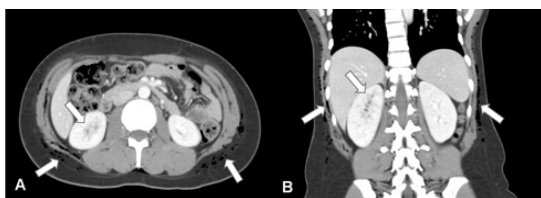


Fig. 1. Massive subcutaneous emphysema, myositis, and pyelonephritis on right kidney from the axial view (A) and coronal view (B) in computed tomography (CT)

Furthermore, we consulted the radiology department to determine the presence of a puncture wound in the peritoneal wall and kidney injury by needle. A radiologist confirmed abdominal myositis and acute pyelonephritis. We opted for medical treatment without surgery and performed an abdominal CT scan as a follow-up after 5 days. The carbon dioxide gas was absorbed and myositis was improved, but the area of low attenuation on the right kidney was unchanged (Fig. 2A and 2B). We stopped antibiotic treatment 7 days later and recommended discharge from the hospital as the blood and urine cultures were negative, laboratory tests were normal, and symptoms were improved.

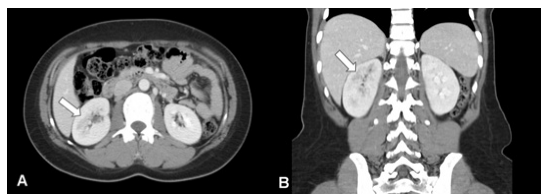

Fig. 2. Pyelonephritis exhibited on the right kidney, but subcutaneous emphysema was absorbed from the axial view (A) and coronal view (B) on CT after 5 days

3. Discussion

Carboxytherapy and mesotherapy are widespread throughout the world because most people prefer therapies that are less invasive than surgery such as liposuction. Carboxytherapy is very similar to

mesotherapy in terms of the methods of the procedure and the conditions it treats. However, an important factor to consider is that carboxytherapy has Food and Drug Administration (FDA) approval, whereas mesotherapy has not yet been approved. In the same vein, there are many reports of mesotherapy complications, but rarely of complications due to carboxytherapy.

Carboxytherapy is a safe, minimally-invasive medical procedure using a micro-needle to inject under the skin into the subcutaneous tissue for improvement of scarring, cellulite, and wrinkle reduction[1-4]. Although the risk of complications with mesotherapy is lower than acupuncture[8-10], many previous cases have reported that complications of mesotherapy such as hematoma, granulomatous panniculitis, cellulitis, and abscesses[5-7], while complications of carboxytherapy have been rarely reported except for the complication of massive subcutaneous emphysema[11]. In the present case, we experienced myositis and acute pyelonephritis as a complication of carboxytherapy. At first when we encountered this patient, we suspected traumatic kidney injury or traumatic peritonitis due to the therapeutic procedure because of the abdominal and flank area tenderness, including peritoneal irritation signs (e.g. Abdominal pain, tenderness and guarding with fever) at the needles injection site. However, we could not find the any evidences of intra-and extra-peritoneal organ injury. We assumed that complications as mentioned above were due to direct bacterial infection at subcutaneous tissue and retroperitoneal space adjacent kidney by needle. Acute pyelonephritis (APN) is an inflammation of the kidney tissue, which is characterized as fever, chill, flank pain and costovertebral angle tenderness[12]. This patient suffered from right costovertebral angle tenderness, fever and chill after invasive therapy on the same site. Moreover, she complaint urinary tract infection sign such as dysuria. Usually APN can occur as a result of cystitis when bacteria move from bladder. The common causative microbial spectrum of APN are *Escherichia coli*, *Enterobacter*, *Enterococci*, *Klebsiella*,

Proteus and Staphylococcus[13]. However, staphylococcus epidermidis was cultured in her urine, not common species. As this test result, the causative bacteria of her APN might come from skin normal flora along with the needle during carboxytherapy. CT is useful modality for diagnosis of APN and to detect anatomical abnormalities associated with urinary tract infection[14]. CT using contrast media shows localized hypodense lesions because of neutrophil infiltration and tissue edema on kidney in patient with APN[15]. In this case, we could diagnose APN by performing CT. Her abdominal CT showed contrast media perfusion defect on infected kidney. This finding was correlated with clinical manifestation and urinalysis (pyuria). For treatment of APN, antimicrobial therapy should be started as soon as possible. The choice of antimicrobial agents is dependent on its severity and microbial resistance. However, common regimenis quinolone, cephalosporin, piperacillin-tazobactam and carbapenems, and so on[16]. We could manage APN and myositis successfully using by third generation cephalosporin(ceftriaxone). In conclusion, Pyelonephritis can even lead to septicemia, which can have fatal consequences. Therefore, rapid evaluation and treatment is required. Emergency physicians should immediately consider CT scans to identify and treatment complications of organ injury in the event of high fever, myalgia, severe back pain, and subcutaneous emphysema after needle therapy or acupuncure. In addition, physical examination should be carefully evaluated for early diagnosis and treatment, even though most of the adverse effects of mesotherapy and carboxytherapy are minor complications without mortality.

References

- [1] A. Matarasso, T. M. Pfeifer, "Mesotherapy and Injection Lipolysis", *Clinics in Plastic Surgery*, Vol.36, No.2 pp.181-192, Apr, 2009.
DOI: <https://dx.doi.org/10.1016/j.cps.2008.11.002>
- [2] G. S. K. Lee, "Carbon Dioxide Therapy in the Treatment of Cellulite: An Audit of Clinical Practice", *Aesthetic Plastic Surgery*, Vol.34, No.2, pp.239-243, Apr, 2010.
DOI: <https://dx.doi.org/10.1007/s00266-009-9459-0>
- [3] R. Nach, H. Zandifar, R. Gupta, J. S. Hamilton, "Subcutaneous Carboxytherapy Injection for Aesthetic Improvement of Scars", *Ear Nose & Throat Journal*, Vol.89, No.2, pp.64-66, Feb, 2010.
- [4] AM. Rotunda, "Injectable treatments for adipose tissue: terminology, mechanism, and tissue interaction", *Lasers in Surgery and Medicine*, Vol.41, No.10, pp.714-720, Dec, 2009.
DOI: <https://dx.doi.org/10.1002/lsm.20807>
- [5] M. D. P. Davis, T. I. Wright, J. M. Shehan, "A Complication of Mesotherapy: Noninfectious Granulomatous Panniculitis", *Archives of Dermatology*, Vol.144, No.6, pp.808-809, Jun, 2008.
DOI: <https://dx.doi.org/10.1001/archderm.144.6.808>
- [6] C. Brandão, N. Fernandes, N. Mesquita, M. Dinis-Ribeiro, R. Silva, H. L. Viana. L., M. Dias, "Abdominal Haematoma - a Mesotherapy Complication", *Acta Dermato-Venereologica*, Vol.85, No.5, pp.446-446, Feb, 2005.
DOI: <https://dx.doi.org/10.1080/00015550510027829>
- [7] P. Wongkitisophon, P. Rattanakaemakorn, S. Tanrattanakorn, V. Vachiramorn, "Cutaneous Mycobacterium abscessus Infection Associated with Mesotherapy Injection", *Case Reports in Dermatology*, Vol.3, No.1, pp.37-41, Feb, 2011.
DOI: <https://dx.doi.org/10.1159/000324766>
- [8] H. Yamashita, H. Tsukayama, N. Hori, T. Kimura, Y. Tanno, "Incidence of adverse reactions associated with acupuncture", *The Journal of Alternative and Complementary Medicine*, Vol.6, No.4, pp.345-350, Aug, 2000.
DOI: <https://dx.doi.org/10.1089/10755530050120718>
- [9] H. M. Langevin, D. L. Churchill, J. Wu, G. J. Badger, J. A. Yandow, J. R. Fox, M. H. Kraq, "Evidence of connective tissue involvement in acupuncture", *The FASEB Journal*, Vol.16, No.8, pp.872-4, Jun, 2002.
DOI: <https://dx.doi.org/10.1096/fj.01-0925fje>
- [10] L. Zhao, F. Zhang, Y. Li, X. Wu, H. Zheng, L. Cheng, F. Liang, "Adverse events associated with acupuncture: three multicentre randomized controlled trials of 1968 cases in China", *Trials*, Vol.24, No.12, No.1, Article ID 87, Mar., 2011.
DOI: <https://dx.doi.org/10.1186/1745-6215-12-87>
- [11] W. M, Calonge, D. Lesbros-Pantoflickova, M. Hodina, B. Elias, "Massive Subcutaneous Emphysema After Carbon Dioxide Mesotherapy", *Aesthetic Plastic Surgery*, Vol.37, No.1, pp.194-197, Feb, 2013.
DOI: <https://dx.doi.org/10.1007/s00266-012-0006-z>
- [12] K. F. Fairley, N. E. Carson, R. C. Gutch, P. Leighton, A. D. Grounds, E. C. Laird, P. H. G. McCallum, R. L. Sleeman, C. M. O'Keefe, "Site of infection in acute urinary-tract infection in general practice", *The Lancet*, Vol.298, No.7725, pp.615-618, Sep, 1971.
DOI: [https://dx.doi.org/10.1016/S0140-6736\(71\)80066-1](https://dx.doi.org/10.1016/S0140-6736(71)80066-1)
- [13] L. K. McLellan, D. A. Hunstad, "Urinary tract infection: Pathogenesis and Outlook", *Trends in Molecular Medicine*, Vol.22, No.11, pp.946-957, Nov, 2016.
DOI: <https://dx.doi.org/10.1016/j.molmed.2016.09.003>

- [14] A. Kawashima, A. J. LeRov, "Radiologic evaluation of patients with renal infections", *Infectious Disease Clinics of North America*, Vol.17, No.2, pp.433-456, Jun, 2003.
DOI: [https://dx.doi.org/10.1016/S0891-5520\(03\)00007-2](https://dx.doi.org/10.1016/S0891-5520(03)00007-2)
- [15] M. Tsugaya, N. Hirao, H. Sakagami, Y. Iwase, H. Watase, K. Ohtaguro, H. Washida, "Computerized tomography in acute pyelonephritis: the clinical correlations". *The Journal of Urology*, Vol.144, No.3, pp.611-3, Sep, 1990.
DOI: [https://dx.doi.org/10.1016/S0022-5347\(17\)39536-8](https://dx.doi.org/10.1016/S0022-5347(17)39536-8)
- [16] K. K. O'Dell, "Pharmacologic Management of Asymptomatic Bacteriuria and Urinary Tract Infections in Women", *Journal of Midwifery & Women's Health*, Vol.56, No.3, pp.248-265, May/June, 2011.
DOI: <https://dx.doi.org/10.1111/j.1542-2011.2011.00063.x>

Kyung-Hoon Sun [Regular member]



- Feb. 2013 : Chosun University, Doctor of Medicine, M.D
- May. 2013 ~ Feb. 2015 : Chosun University Hospital Clinical Fellow
- Mar. 2015 ~ Feb. 2016 : Inje University Haeundae Paik Hospital Clinical assistant professor
- Mar, 2016 ~ current : Chosun University, College of Medicine, Professor

<Research Interests>

Biomedical & Bioengineering, Clinical medicine

Jun-Ho Heo [Regular member]



- Feb. 2010 : Wonkwang University, Bachelor of Medicine
- Feb. 2015 : Korean Society of Emergency Medicine, Emergency Physician
- May. 2018 ~ current : Wonkwang University Hospital Clinical Fellow

<Research Interests>

Biomedical & Bioengineering, Clinical medicine

Yong Hwang

[Life member]



- Feb. 2009 : Wonkwang Univ, Master's degree in Medicine,
- Feb. 2010 : Korean Society of Emergency Medicine, Emergency Physician
- Mar. 2010 ~ Aug, 2013 : Wonkwang University Hospital Clinical assistant professor
- Sep. 2013 ~ current : Wonkwang University, College of Medicine, Professor

<Research Interests>

Biomedical & Bioengineering, Clinical medicine